



Management of Ptosis

Seriousness of complication		Frequency of complication	
Minor complication		Common	
Worrying complication		Occasional	
Moderate complication	X	Infrequent	X
Serious, but not major		Rare	
Major complication		Very rare	

Title	Management of Ptosis		
Authors	Dr Martyn King		
Date	May 2014	Review Date	May 2016
Version	1.2		

Management of Ptosis

Definition:

Ptosis is derived from the Greek word for falling and is the medical terminology describing a drooping or abnormal lowering of an anatomical area. When ptosis pertains to the eyelid it is more accurately described as blepharoptosis.

Introduction:

In aesthetic medicine, ptosis is almost exclusively related to the inadvertent injection of botulinum toxin type A into an unwanted area leading to muscle weakness and a resultant droop, particularly in the hands of an inexperienced injector. Depending on the area treated, ptosis can affect the brow resulting in a lowering of the eyebrows which produces a poor cosmetic result but can also lead to a significant descent of the eyebrows which may interfere with vision. Upper lid ptosis may occur when treating the glabellar complex and botulinum toxin type A diffuses through the orbital septum and affects the lid elevator muscle either as it traverses the pre-periosteal plane or the toxin may track along tributaries of the superior ophthalmic vein¹. This may result in a drooping of the upper lid with the patient unable to fully open the eye, a poor cosmetic result and may interfere with normal vision.

Although ptosis may persist for the whole duration of effect of treatment with botulinum toxin type A, it will usually settle more quickly and eye lid ptosis will often settle within 3-4 weeks and brow ptosis within 6 weeks^{2,3}.

Incidence:

Allergan's Multicentre FDA study revealed a 5.4% incidence of ptosis (12 out of 263), however it was acknowledged that many of these complications were as a result of an inexperienced injector. The reported incidence of experienced injectors is far less than this and more likely to be less than 1%⁴.

Signs and symptoms of ptosis:

The patient will normally present within 3 – 7 days complaining of a drop of the brow or eyelid. Ptosis can be unilateral or bilateral. Sometimes the ptosis is subtle and although may not be immediately apparent, the patient will feel that the lid or brows feels heavy and they may not be able to fully open their eye and may struggle to put on their eye makeup. The patient may describe fatigue and heaviness around the eye which worsens throughout the day⁵. In some situations the ptosis can be severe and lead to restriction of vision.

Risk factors:

- Patient factors (Age, lifestyle factors, heavy brow, short brow, outdoor working resulting in sun damage, loss of elasticity, heavier skin and a greater reliance on the action of the frontalis muscle)
- Medical conditions (Previous facial surgery, neurological conditions such as myasthenia gravis and caution in multiple sclerosis, previous history of ptosis or Bell's palsy)
- Product factors (Product dilution, product quality)
- Treatment factors (Injection technique, injection placement, dosage)

Minimising the risk of ptosis:

Ensure a full medical history is taken to include any pre-existing conditions and obtain consent after advising on the risks of side effects and complications including a potential ptosis. Next assess the patient's anatomy and musculature, pay particular attention to the brow position (the anatomical brow rather than the actual brows which may have been cosmetically altered) and any pre-treatment asymmetry (approximately 90% of the population have a degree of brow asymmetry²). Assess brow size and heaviness with particular attention to the resting tone of frontalis to ensure that the patient is not using this muscle at rest to support the brows (ask the patient to sit upright, look forward and then to close their eyes, if the eyebrows descend during this check, do not treat the forehead lines²). Photographs should always be taken prior to treatment. Post-treatment inform the patient to avoid sunbathing, saunas and massage for at least 4 hours which may lead to greater spread of the toxin⁴.

Brow ptosis

“The only important side-effect of forehead treatment with botulinum toxin type A is brow ptosis and this can be reduced with simple rules.”⁴

1. When treating the frontalis muscle, always inject at mid forehead or above (at least 2cm above the brow in all patients and for older patients, ensure injections are at least 4cm above the brow²).
2. By injecting intradermal rather than intramuscular when treating the forehead, one study reported a lower incidence of ptosis with no reduction in results⁴.
3. Always inject the glabellar at the same time as the forehead (never treat the frontalis muscle in isolation), particularly in patients over 50 years of age² (treating the brow depressors at the same time as the elevator muscle) and if the practitioner anticipates problems with the forehead, it is recommended to inject the glabellar first and then reassess the forehead in 2 weeks. As with all botulinum toxin type A treatments, if in doubt, use conservative amounts and reassess the need for additional units at review.
4. Be cautious in any patient who has had previous frontal facial surgery⁶.

Eyelid ptosis

1. Injections should always remain 1cm above the brow and not lateral to the mid-pupillary line when treating the glabellar².
2. During injection of the corrugator supercilii muscles, use digital pressure over the supraorbital rim with the non-injecting hand to reduce the risk of diffusion².

3. When injecting around the glabellar complex, the needle should be pointing superiorly away from the orbit⁷.
4. When treating under the eye during the treatment of crow's feet, the botulinum toxin type A should never be injected medial to the mid-pupillary line and must remain at least 1cm away from the margin of the orbit. Never inject immediately below the eye if there is a significant degree of scleral show pre-treatment, if there has been previous eye surgery or if there is a negative snap-test (eyelid extraction test) with a delay in the skin below the eye returning to its normal position after being manually pulled down.

Lip ptosis

1. When treating the crow's feet, ensure injections remain within the confines of the orbicularis oculi muscle. If treating too inferiorly, it is possible that the zygomaticus major muscle may be affected. This muscle arises from the anterior zygoma and is responsible for lifting the corner of the mouth up and laterally. Ptosis in this area becomes more apparent when the patient is asked to smile.
2. Lip ptosis may also occur when treating smoker's lines and over-administration of botulinum toxin type A to the orbicularis oris muscle. Only small doses are required in this region and it should only be performed by experienced injectors.

Treatment of ptosis:

A full explanation and reassurance to the patient advising the likely duration of effect will suffice for many patients if the ptosis is relatively mild.

Eyelid ptosis

Stimulation of the muscle may help to lessen the duration of the ptosis, this can be done either by exercising the muscle or mechanical or electrical stimulation. A well known trick that is performed by many practitioners is the use of the back of an electric toothbrush over the muscle for several minutes a day.

If the upper eyelid ptosis requires treatment, 0.5% apraclonidine eye drops can be prescribed at a dosage of 1-2 drops three times a day. This is an alpha-adrenergic receptor agonist and a mydriatic agent which causes contraction of Müller's muscle (also known as the superior tarsal muscle, it is an adrenergic muscle situated beneath the levator muscle, approximately 12mm in length and is an involuntary muscle supplied by sympathetic nerves) and may elevate the lid by 1 -2 mm⁷. There is greater evidence for the successful use of apraclonidine to treat ptosis in Horner's syndrome⁸. There is a risk of causing miosis and closed angle glaucoma in susceptible individuals and it is prudent to check whether a patient wears glasses and their ophthalmic medical history. Apraclonidine is generally well tolerated but may cause some sensitivity of the eye with longer term use.

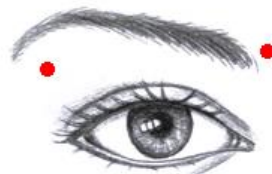
Lower lid ptosis may occur due to the overtreatment of the palpebral portion of the orbicularis oculi muscle and can have a significant impact on the functionality of the eyelid. There is no specific treatment for this complication and it usually settles within a matter of

weeks, however if an ectropion develops, prompt ophthalmological referral is recommended to prevent exposure keratitis and corneal damage⁹.

Brow ptosis

A study conducted by Alastair and Jean Carruthers has previously shown that treating the glabellar complex using a 7 injection point technique and between 20-40 Units of onabotulinumtoxinA produced significant changes in eyebrow position with an average elevation of 0.5 – 1.3mm depending on dosage and the part of the eyebrow (medial, central or lateral)¹⁰. Interestingly the lateral part of the brow responded the earliest so it is thought that the elevation is caused by botulinum toxin type A diffusing into the medial fibres of the frontalis muscle with partial inactivation and a resultant compensatory increased resting tone throughout the whole frontalis muscle.

If a brow ptosis occurs, intradermal injection of 0.01ml (5 Speywood Units, Dysport) 2-3mm below the lateral brow and a further 0.01ml (5 Speywood Units, Dysport) deep injection to the corrugator at the medial brow can reduce the action of the brow depressors and result in a 1-2mm brow raise⁴ (the author recommends 2 Units of onabotulinumtoxinA [Botox®, Vistabel®] or incobotulinumtoxinA [Bocouture®, Xeomin®] if used instead of abobotulinumtoxinA [Azzalure®, Dysport®] with a similar 0.01ml dilution to prevent excessive spread and the risk of further complication). If a brow raise cannot be achieved, careful lowering the other side to provide symmetry and a better aesthetic result may be possible. These compensatory treatments should only be performed by an experienced practitioner.



One case report in the literature showed an improvement in botulinum toxin type A induced ptosis by the administration of pyridostigmine bromide at a dose of 60mg every 6-8 hours¹¹. Pyridostigmine bromide is an orally active cholinesterase inhibitor that is used to treat myasthenia gravis. However dosage and frequency is dependent on the individual and side effects are common including severe muscle weakness, it is not a recommendation from the Aesthetic Complications Expert Group.

Finally, if the ptosis is causing restriction of vision, the brow or lid may need taping up to remove it from the field of vision.

It is worth mentioning that botulinum toxin type A is sometimes used to purposely create a ptosis to correct lid malposition and eyelid fissure asymmetries¹².

Follow-up

All patients presenting with ptosis should be carefully followed-up and photographs should be taken to objectively assess over time. Eyelid ptosis can be objectively documented by a measurement known as MRD (margin reflex distance). The patient sits vertically upright and looking straightforward at a penlight. The distance from the eyelid margin to the corneal light reflex is the MRD and is usually greater than 2.5mm⁷.

If the ptosis persists, it would be sensible to consider referral to a practitioner who has more experience in this area.

Good follow up and client support and full explanations to the client is the best approach to stop a complication turning into a medical malpractice claim!

References

1. Ramey NA, Woodward JA. Mechanisms of blepharoptosis following cosmetic glabellar chemodenervation. *Plastic and reconstructive surgery* 2010;126:5;249-250.
2. Klein AW. Complications and adverse reactions with the use of botulinum toxin. *Seminars in Cutaneous Medicine and Surgery* 2001;20:2;109-120.
3. Nettare K, Maas C. Facial filler and neurotoxin complications. *Facial Plast Surg* 2012;28:3;288-293.
4. Redalli A, Forte R. How to avoid brow ptosis after forehead treatment with botulinum toxin. *J Cosmetic and Laser Ther* 2003;5:220-222.
5. Fagien S. Temporary management of upper lid ptosis, lid malposition, and eyelid fissure asymmetry with botulinum toxin type A. *Plastic and reconstructive surg*, 2004;114:7, 1892-1902.
6. Prado AC. Caution in using botox in patients with previous frontal surgery. *Plastic and reconstructive surg* 2002;109:4;1472-1473.
7. Omoigui S, Sunday I. Case report: Treatment of ptosis as a complication of botulinum toxin. *Pain medicine* 2005;6:2;149-151.
8. Jose M, Brown SM, Abdul-Rahim AS, Crosson CE. Ocular effects of apraclonidine in Horner syndrome. *Arch Ophthal* 2000;118:951-4.
9. Vartanian AJ, Dayan SH. Complications of botulinum toxin A use in facial rejuvenation. *Facial Plast Surg Clin N Am* 2005;13;1-10
10. Carruthers A, Carruthers J. Eyebrow height after botulinum toxin type A to the glabella. *Derm Surg* 2007;33:S1;526-531.
11. Karami M, Taheri A, Mansoori P. Treatment of botulinum toxin induced eyelid ptosis with anticholinesterases. *Derm Surg* 2007;33:11;1392-1395.
12. Yücel OE, Artürk N. Botulinum toxin-A-induced protective ptosis in the treatment of lagophthalmos associated with facial paralysis. *Ophthal Plast Reconstr Surg* 2012;Jul-Aug;28(4):256-60.

Management of Ptosis

Author

Dr Martyn King

Expert Group

Dr Martyn King

Emma Davies RN NIP

Dr Stephen Bassett

Sharon King RN NIP

Consensus Group

Dr Raj Acquilla

Dr Ben Coyle

Dr David Ecclestone

Dr Ravi Jain

Dr Harryono Judodihardjo

Dr Patrick Treacy

Constance Champion RN NIP

Helena Collier RN NIP

Sponsors

